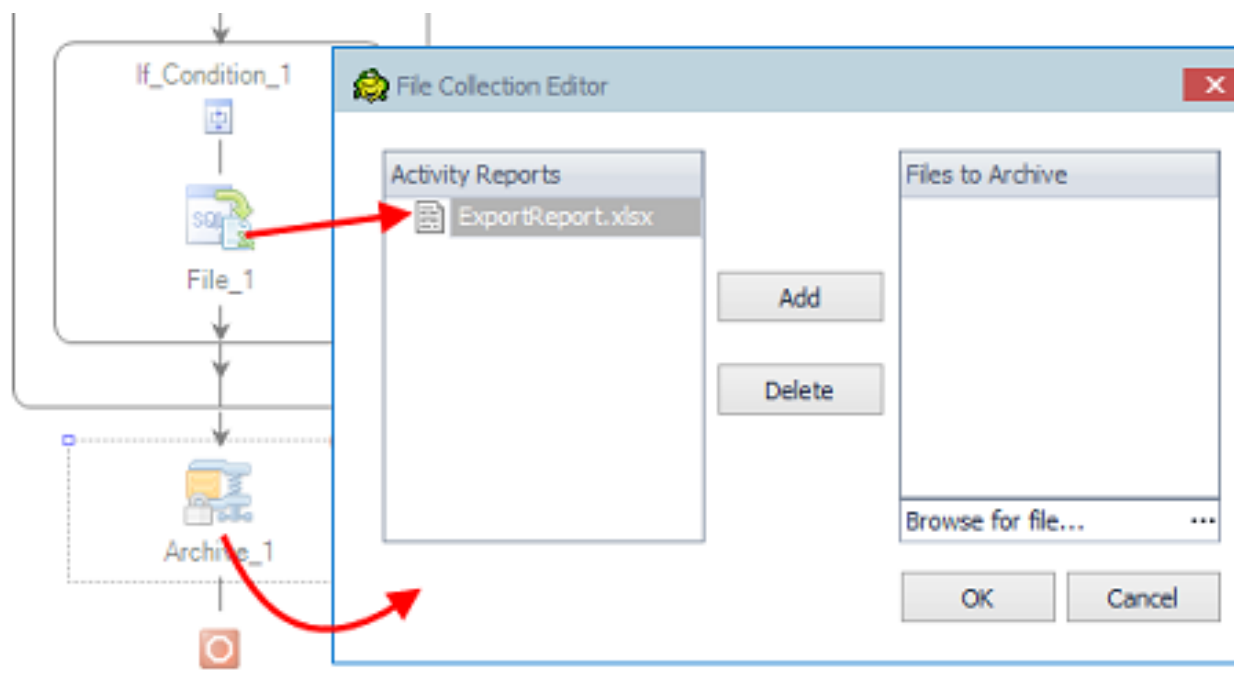


Rar Sb3utility Download Windows Full Version



DOWNLOAD: <https://byltly.com/2ip6et>

Download

.gloabl +----+-----+----+ | id | name | id | |----+-----+----+ New model for live-born mouse pregnancy. A model of live-born mouse pregnancy was designed and used to evaluate the effects of maternal hypoxia and hypercapnia on fetoplacental growth and fetal survival. Pregnant NMRI mice were anaesthetized with a mixture of ketamine and xylazine, and right abdominal wall incisions were made. The uterine horns were cannulated with silicone rubber tubing and plastic cannula was inserted into the left uterine horn to prevent distension and to allow sampling of the amniotic fluid. A micropipette was used to measure amniotic fluid pH. Maternal arterial and amniotic fluid PCO₂ values were recorded by mass spectrometry. Saline was infused through the uterine tubes to maintain intra-amniotic pressure and amniotic fluid volume. Day 15 mouse conceptuses were injected with 3H-thymidine or 131I-bovine serum albumin and transferred to a cage with a neonate of similar age. Day 19 embryos were examined histologically for growth retardation and fetal survival. Maternal arterial and amniotic fluid PCO₂ values decreased after pregnancy was established (mean arterial PCO₂ 26.6 and mean amniotic fluid PCO₂ 23.8). At gestation day 15 the placental weight was 35% of that of nonpregnant controls (P less than 0.05). On gestation day 19 fetal survival was 82% after exposure to maternal hypoxia (P less than 0.05). The model is simple, inexpensive, reproducible and facilitates study of fetal growth and survival in experimental animals. Tuberculous bacillary angiomatosis. We describe a case of tuberculous bacillary angiomatosis with pustular cutaneous lesions, involving the legs and buttocks. The patient, an elderly female, had a history of pulmonary tuberculosis and non-Hodgkin lymphoma. She was diagnosed with tuberculosis by transbronchial lung biopsy and was treated with antituberculous agents. The lesions of tuberculous bacillary angiomatosis improved with treatment, and a skin biopsy specimen showed no evidence of tuber 82157476af

Related links:

[mathcad 15 license dat](#)

[Spectrasonics Trilian v 1.4.1d x86 x64 Setup KeyGen](#)

[HACK Adobe Photoshop Lightroom CC 2018 v12.1.3.16 PC](#)